

Approach to Abdominal Pain in Sickle Cell Anaemic Patients

1. Basim AA. Al Hijjaj
2. Sadik Hassan

Received 2nd Apr 2023,
Accepted 19th May 2023,
Online 30th May 2023

¹ F.I.C.M.S) consultant pediatrician , Basra center For hereditary Blood diseases, Member of Iraqi Association for Medical Research and Studies (IAMRS),
² (FICMS, pediatric surgery) Assistant Professor, Consultant Pediatric Surgeon, Al-Zahraa Medical College, University of Basrah
Corresponding author: Basim AA. Al Hijjaj
Email:
basim.abdulkarem@avicenna.uobasrah.edu.iq

Abstract: Sickle cell disease is the term that involve both homozygous sickle cell anemia and the heterozygous sickle cell thalassemia disease. (1)

As a result of a single amino acid substitution (valine for glutamic acid at the $\beta 6$ position), sickle hemoglobin crystallizes and forms a gel in the deoxygenated state. When reoxygenated, the sickle hemoglobin is normally soluble. The so-called reversible sickle cell can enter the microcirculation. As the oxygen is extracted and saturation declines, sickling may occur, occluding the microvasculature. The surrounding tissue undergoes infarction, inducing pain and chronic organ dysfunction. This sickling phenomenon is exacerbated by hypoxia, acidosis, fever, hypothermia, and dehydration. (2)

Musculoskeletal, chest, and abdominal pain are remarkable manifestations of the sickling.

Sickle cell patient with abdominal pain is one of the common presentations of the disease and one of its clinical dilemmas that impose itself to be discussed and clarified.

Key words: sickle, abdominal pain, anemia

Classification:

For a clinical purpose we can classify the pain into acute (few days since onset), and chronic (lasted or recur for long period).

While an arbitrary interval, such as 12 weeks, can be used to separate acute from chronic abdominal pain, there is no strict time period that will classify the differential diagnosis unflinchingly. A clinical judgment must be made that considers whether this is an accelerating process, one that has reached a plateau, or one that is longstanding but intermittent:

- Pain of less than a few days duration that has worsened progressively until the time of presentation is clearly "acute."
- Pain that has remained unchanged for months or years can be safely classified as chronic.⁽³⁾

Acute abdominal pain: main causes

1. Acute cholecystitis
2. Gallstone (Biliary colic)
3. Common bile duct stone
4. Mesenteric vascular occlusion.
5. Acute vaso-occlusive pain.
6. Drug induced gastropathy as (NSAID)
7. Gastritis
8. Nephrolithiasis, urinary tract infection, renal infarcts
9. Basal pneumonia

Chronic abdominal pain: main causes

1. Chronic cholelithiasis.
2. Recurrent calculous cholecystitis.
3. Non remitting vaso-occlusion.
4. Drug induced (defrasirox, tonics, zinc compounds, etc.)⁽³⁾

Clinical conditions:

Acute cholecystitis

Right upper abdominal pain, vomiting, fever, rigor, increasing icteric tinge, dark color urine, ill toxic patient.⁽²⁾ Tender right hypochondrium, positive Murphy sign, fever, jaundice

Diagnostics tools:

Complete blood count (CBC): leukocytosis with absolute neutrophilia, low hemoglobin (Hb)

Liver function test: Raised total serum bilirubin (TSB) and direct bilirubin.

General urine examination: dark yellowish gross color inspection, positive bile

Ultrasonic examination is the major diagnostic tool (inflamed edematous gall bladder, possibly stone containing)

Treatment:

Patient is to be admitted to the ward, heavy antibiotics(ceftriaxone, aminoglycoside, metronidazole **or** meropenem in culture based decision or ceftazidime if pseudomonas spp. is suspected or confirmed, non-narcotic analgesia.

Vaso-occlusive abdominal pain.

Clinically presented as diffused ill defined, dull aching pain, agitated child. Could be occur as isolated painful condition or as a part of generalized vaso-occlusive crises.⁽⁴⁾ Constipation usually occur since the onset of the crises or after using narcotics as analgesia. On abdominal examination; there is diffused tenderness, sometimes rigid abdominal wall, bowel sound is positive.

Diagnostics tools:

CBC Normal white blood cell count and differential,
raised serum LDH, LFT usually normal

Treatment: escalating analgesia start from oral paracetamol to the extreme of use the narcotic analgesia(consider antiemetics, laxative) according to the relevant guidelines ^(5,6)

Nephrolithiasis

Unilateral or bilateral loin pain or even diffused abdominal in younger children with or without one of the following

- Dysuria
- Urgency
- Suprapubic pain
- Hematuria
- Interrupted urine stream

N.B: renal impact of Sickle cell disease (SCD) may include the following ⁽⁷⁾

1. Nephrolithiasis
2. Hyposthenuria
3. Renal infarction
4. Papillary necrosis
5. Urinary tract infection
6. Nephrotic syndrome

Diagnostic tools: Urine analysis, ultrasonography

*Treatment:*according to the diagnosed condition ,almost parenteral or oral NSAID,hydration and possibly antibiotics for pyelitis or cystitis .

Mesenteric vascular occlusion

Rare cause of the condition, expected in patients with abrupt and sever abdominal pain associated with possible collapse, bowel sound is typically negative. ^(8,9)

Diagnostic tools:

1. CBC
2. Serum LDH level
3. D dimer assay
4. Ultrasonography

Whoever none of the above is specific diagnostic.

Mesenteric angiography supported by doppler ultrasonography is a specific diagnostic tool .

Chronic cholelithiasis

Chronic or recurrent manifestations mentioned for the acute one

Drug induced acute or chronic pain

Should always be anticipated and suspected in any acute or chronic abdominal pain in sickle cell patient

Diagnostic tools: ⁽¹⁰⁾

1. Careful history
2. Endoscopy

Sequestration major:

Although most of the sequestration crises are almost painless but massive splenomegaly may be a cause of abdominal pain and distension, ⁽¹⁰⁾ left hypochondrial pain, localized distension, collapsed pale child and extremely palpable spleen are all characteristic feature for this clinical entity.

Diagnostic tools

1. CBC: low haemoglobin (at least 2gm/L from baseline), low platelets count, high reticulocytes count.
2. Ultrasonography

N.B

In addition to all of the above non specific causes (for non sickle cell patients) may be attributed to be a cause of abdominal pain in sickle cell patients

As follows

Causes of childhood nonspecific acute abdominal pain.

1. Mesenteric adenitis
2. Appendicitis
3. pancreatitis
4. Hepatitis
5. Meckel's diverticulitis
6. Gynaecological causes in adolescent females like dysmenorrhea ,Ovarian torsion ,ectopic pregnancy.ect

Diagnostic Tools:

1. Ultrasonography
2. Computerized tomography
3. Meckel's scan
4. Serum amylase and lipase

Causes of childhood nonspecific chronic or recurrent abdominal pain.

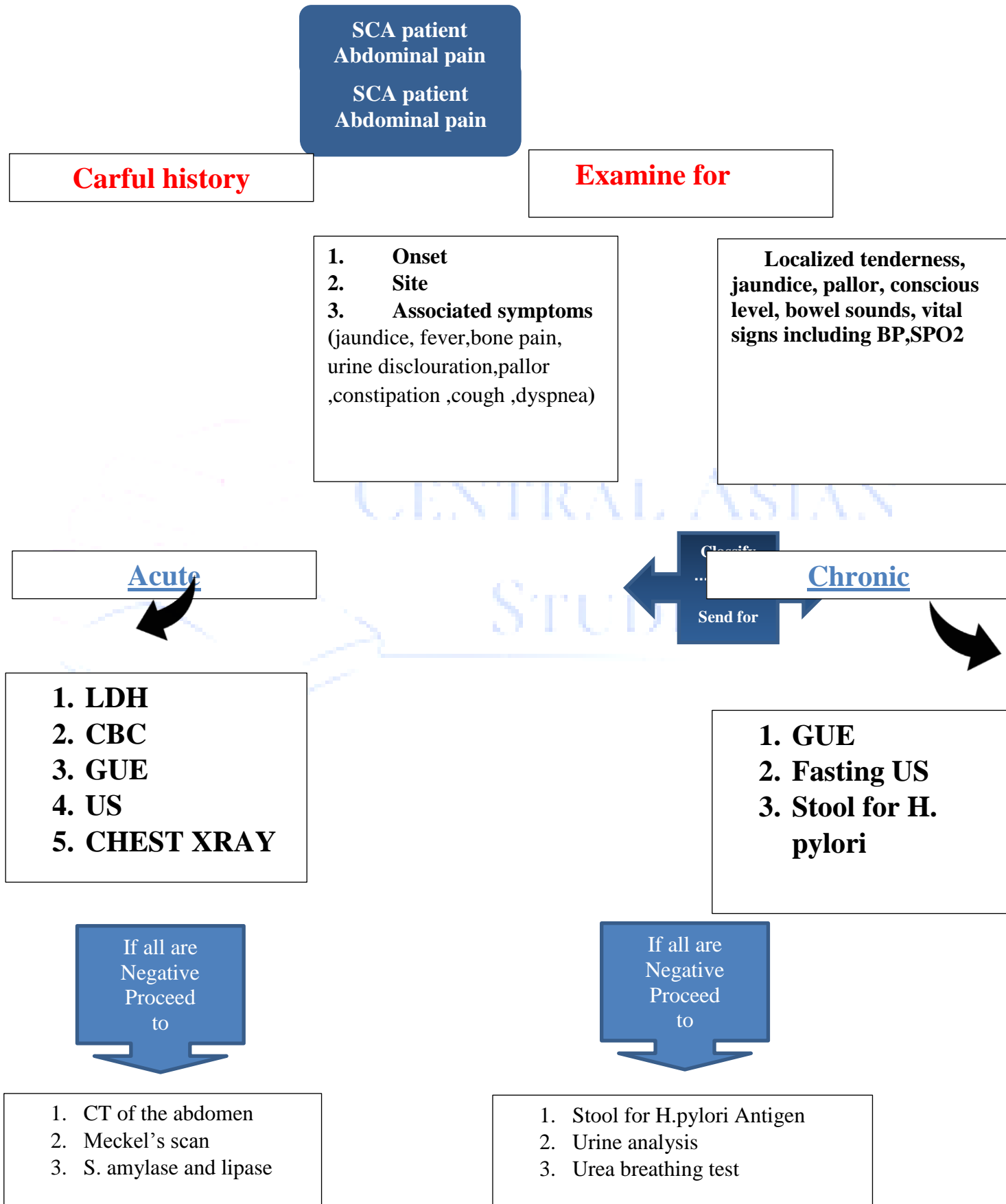
1. Functional abdominal pain
2. H. Pylori gastritis ^(11,12)
3. Constipation
4. Urinary tract infection

All these cause should also be ruled out and excluded as a final accomplishment.

Diagnostic tools

1. Stool for H. pylori antigen
2. Urine analysis
3. Urea breathing test
4. Ultrasonography

in summary, the following approach could be followed



References:

1. Ohene-Frempong K. Sickle cell disease in the United States of America and Africa. *Hematology (Am Soc Hematol Educ Program)* 1999: 64 –72.
2. Karen J. Marcidante, Robert M. Kliegman, Wisconsin Abigail M. Schuh, Md, Nelson Essentials Of Pediatrics, Sickle Cell Disease, P 594-612.
3. Robert M Penner, Sumit R Majumdar. Diagnostic approach to abdominal pain in adults. UpToDate 13.1 available from <https://sites.ualberta.ca/~loewen/Medicine/GIM%20Residents%20Core%20Reading/ACUTE%20&%20CHRONIC%20ABDO%20PAIN/Diagnostic%20approach%20to%20abdo%20pain.htm>
4. EVIDENCE-BASED MANAGEMENT OF SICKLE CELL DISEASE: EXPERT PANEL REPORT, 2014. Vaso-Occlusive Crisis, p.32
5. Ballas SK. Pain management of sickle cell disease. *Hematol Oncol Clin North Am.* 2005;19(5):785-802.
6. Ballas SK. The sickle cell painful crisis in adults: phases and objective signs. *Hemoglobin.* 1995;19(6):323-33.
7. Nath, Karl A, and Robert P Hebbel. "Sickle cell disease: renal manifestations and mechanisms." *Nature reviews. Nephrology* vol. 11,3 (2015): 161-71. doi:10.1038/nrneph.2015.8
8. Abadin SS, Salazar MR, Zhu RY, Connolly MM, Podbielski FJ (2009) Small Bowel Ischemia in a Sickle Cell Patient. *Case Rep Gastroenterol* 3: 26-29. [Crossref]
9. van der Neut FW, Stadius van Eps LW, van Enk A, van de Sandt MM (1993) Maternal death due to acute necrotizing colitis in homozygous sickle cell disease. *Neth J Med* 42: 132-1323.
10. Kane I, Kumar A, Atalla E, et al. Splenic Sequestration Crisis. [Updated 2022 May 1]. In: StatPearls [Internet]. Treasure Island (FL): StatPearls Publishing; 2022 Jan-. Available from: <https://www.ncbi.nlm.nih.gov/books/NBK553164/>
11. Bates I, de Caestecker J. Sickle cell disease and risk of peptic ulceration. *Trans R Soc Trop Med Hyg.* 1996 May-Jun;90(3):292–292.
12. Woods KF, Onuoha A, Schade RR, Kutlar A. Helicobacter pylori infection in sickle cell disease. *J Natl Med Assoc.* 2000 Jul;92(7):361-5. Erratum in: *J Natl Med Assoc* 2000 Dec;92(12):A22. PMID: 10946532; PMCID: PMC2608584.