

The importance of the ulnar osteotomy in the treatment of chronic radial head dislocation in children

Xodjanov I.Y.
Edilov U.A.
Shamatov X.Sh.
Lutpillaev A.X.

Received 5th March 2021,
Accepted 15th March 2021,
Online 27th March 2021

Republican Specialized Scientific and
Practical Medical Center of Traumatology
and Orthopedics, Pediatric Traumatology
Department

ABSTRACT: A year ago, our clinic offered a new method of treating radial head dislocations (fixation with part of muscle taken from *m. anconeus*). Now it is possible to perform this method in the ulnar osteotomy with long chronic dislocations of radial bones. In this article, it is shown that 55 patients are successfully treated by those methods. Correctional and elongated ulnar osteotomy are done in all patients, the radial head was easily replaced. Studies have confirmed that, chronic radial head dislocations in children are the result of misdiagnosing and inaccurate treatments of this pathology in the elbow joint. Observations and examinations have displaced that, osteotomy on ulnar bone is still beneficial procedure for treating chronic radial head dislocations and other innovative methods should be used by including this method.

Key words: Trauma Bracht, radial bone, annular ligament, trauma Montage

Importance of the topic

Chronic radial head dislocations are common issue in modern traumatology and orthopedics till these days. [2.7.4.5.7.] Anatomical and biomechanical disfunctions, reducing movement capacity, neurotrophic changes and lateral instability are the remains of chronic radial head dislocations. This, in turn, leads to long-term ulnar dysfunction and limited selfcare in patients. [9.10.14.19] According to the literatures, chronic radial head dislocations account for approximately from 1.9% to 2.7% of all elbow joint injuries. [2.5] Whereas, this pathology occurs a lot in children, 86%. [18.21.22]

Chronic radial head dislocations are common in 3-14 ages and it is explained high activity of children in this age. One of the main reason of this pathology is misdiagnosing and inaccurate treating of fractured, dislocated bones. According to the literatures, bones of forearm fractures and dislocations

account for 6% of all forearm fractures. [1.3.9.11] There are 3 types of forearm fractures and dislocations in basic literatures. Montage injury (diaphysial fracture of ulnar bone with dislocation of radial head), Bracht injury (metaphyseal fracture of ulna and dislocation of radial head) and Malgaigne injury (epiphyseal fracture of ulna and dislocation of radial head). Among these injuries, trauma Montage is relatively common. Trauma Montage is also divided into 4 types: [2.5.7.8.12]

Type 1. It is characterized Diaphysial fracture of ulnar bone with forward dislocation of radial head. This type accounts for 70% of Montage injury.

Type 2. It is characterized Diaphysial fracture of ulnar bone with backward dislocation of radial head and it often occurs in children older than 13 ages. This type accounts for 3-6% of Montage injury.

Type 3. It is characterized metaphyseal fracture of ulnar bone and forward and outwards dislocation of radial head, it accounts for 23% of Montage injury.

Type 4. It is characterized diaphysial fracture of ulna and distal fracture of radius with forward dislocation of radial head. This type of injury accounts for only 1% of Montage injury (2 fractures and 1 dislocation). [14.16.19.20.]

Separated dislocation of radial head is rarely observed and it is only congenital. Incorrectly diagnosing and treating of all types of fractures and dislocations on time lead to a chronic dislocation of radial bone.

Because of those fractures and dislocations, radial bone dislocates and ulnar bone bends and may shorten in length, in this case, after repairing process the forearm segment decreases in length. The head of the radius may not fit if it is replaced, and aseptic necrosis of the radial head may occur during forced reduction, after that this leads to ulnar joint contraction. To eliminate this pathological mechanism, reduction of radial head is done by correcting the deformity of ulnar bone and ensuring the length of the forearm segment. There are some vital aspects in process of using those methods cannot be omitted. That is, fixing the radial head in place, where and how to perform an osteotomy of ulnar bone, such as possibility of performing these two operations simultaneously and obtaining an early functional result. These problems are always difficult to solve positively and require deep scientific research.

Now days different method are being used in many countries for the operative treatment of chronic radial head dislocation. Due to some dilemmas of these methods, it leads to incomplete recovery of anatomical and biomechanical function in the elbow joint, also appearing recurrences as well. For this reason, the research about the chronic radial head dislocations still needs optimal solution and developing operative methods of ulnar osteotomy shows the importance of this topic today.

Purpose

Determination of the functional status of the elbow joint in patients who experienced proximal part of the ulnar osteotomy by traditional fixing chronic radial head dislocations (fixation with part of muscle taken from m. anconeus).

Subject and method of checking

In 2019-2020, in the Department of Pediatric Traumatology of Republican Specialized Scientific and Practical Medical Center of Traumatology and Orthopedics, 55 patients were operatively treated with a diagnosis of chronic radial head dislocation. The age of patients under observation ranged from 3 to

17 years. (diagram №1) and they were received at different times after the injury. Patients were treated primarily first aid at the place and with a cast. The remaining cases were treated by local doctors (who does not have knowledge about modern medicine). Patients referred for a period of 3 weeks to 5 years(diagram №2). There are 25 boys and 20 girls. Complication of right-sided trauma were observed in 23 patients and left sided trauma in 22 patients as well. All of these patients checked by X-ray, MCT, ultrasound examinations. In all patients, except chronic radial head dislocations, fracture of ulna was found to be inaccurately treated (Bracht and Montage traumas), Trauma Malgaigne did not appear (diagram №3).

Osteotomy was performed to correct and elongate the ulna from the apex of the deformity, due to the deformity of ulna, the difficulty of radial head reduction and increasing the relative ulnar length. After the osteotomy of ulna, correction and traction were done and osteosynthesis was performed by using crossing wires, as result, it allowed to complete a radial head reduction. In all patients the elbow joint was arthrolyzed and plastic surgery of annular ligament was performed by using a new method developed in our clinic, and transarticular fixation was done with Ilizarov wires. After surgery, all patients fixated with longitudinal plastic casts(diagram №3). Transarticular wires were removed after 2-3 weeks and allowed to make movements in the elbow joint.

In order to compare 23 patients who experienced elbow osteotomy and 22 patients who did not experience osteotomy were selectively studied(who were fixed with part of muscle of m.anconeus) for close and long-term results.

Diagram №1

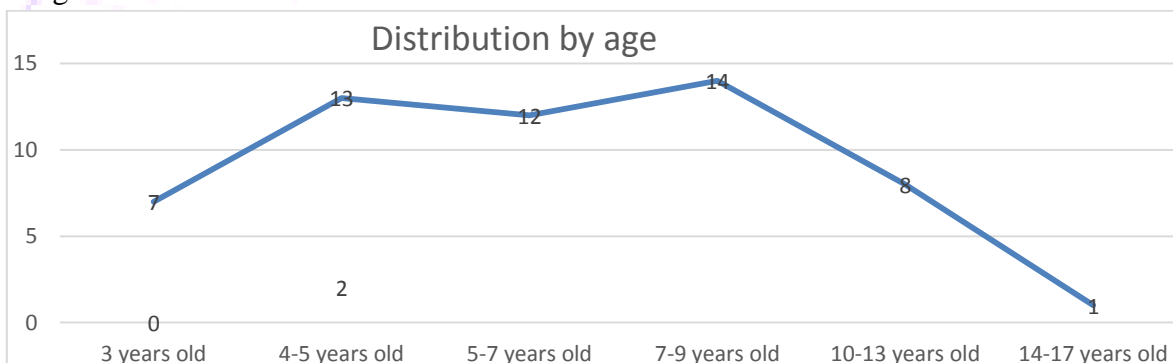


Diagram №2

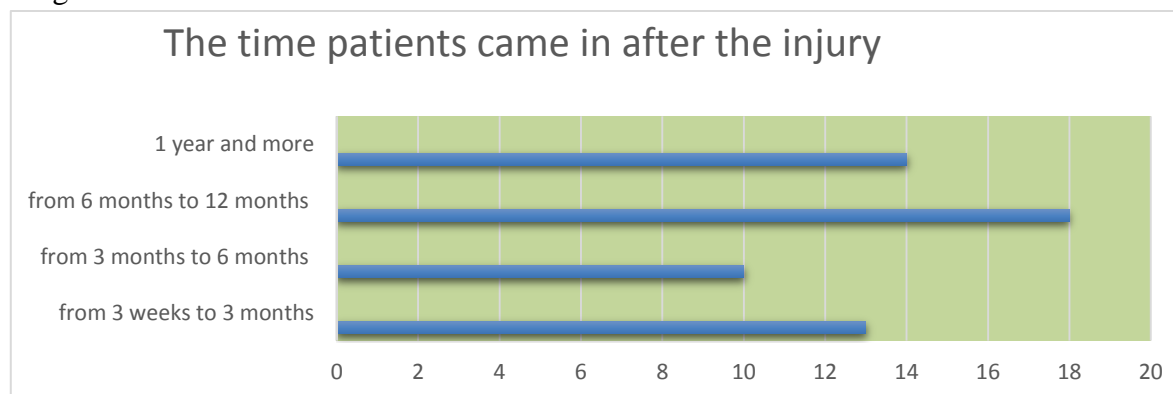
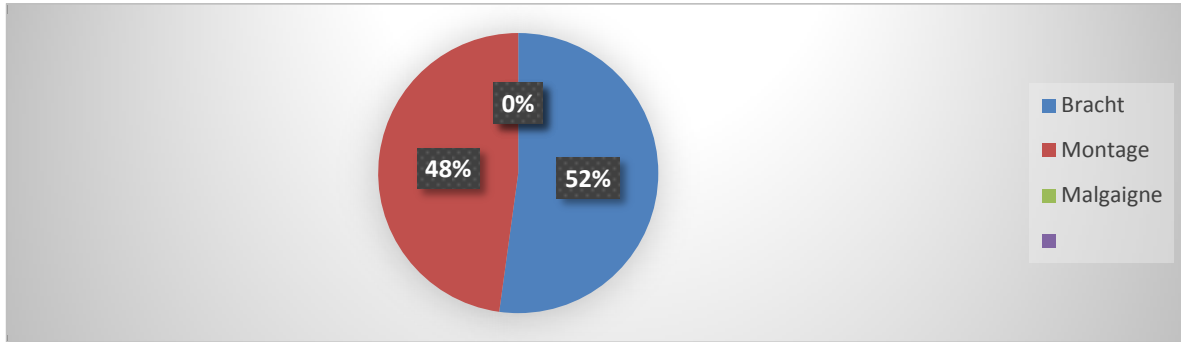


Diagram №3



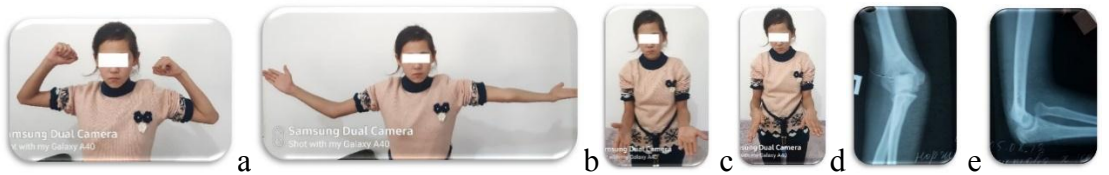
Results

The Bromberg Morray scale was used to evaluate results. This evaluates by determining the amount of movements in the elbow joint (1), the volume of rotational movements (2), the loss of pain in the elbow joint (3), and strength of the radial muscles (4). After elbow osteotomy, anatomical and biomechanical structures of the elbow joint was recovered by using new method, which allowed to make moves in the elbow joint and eliminate the instability.


In all of the treated patients, correction and extension(oblique) osteotomy was performed from the apex of the elbow deformity, followed by traction of the radius resulting an easy reduction of radial head. The elbow, which an osteotomy was done, was made correction, traction and osteosynthesis using intersective wires. Then, a musculoskeletal leg was separated from m.onconeus, plastic surgery of annular ligament was performed, and made transarticular fixation with Ilizarov wires. After surgery, all patients experienced longitudinal plaster cast, transarticular wires were removed within 2 weeks and the use of the elbow joint began. The wires remained in place for 1-1.5 months in patients who experienced corrective osteotomy on the elbow joint until the ulnar bone was healed.

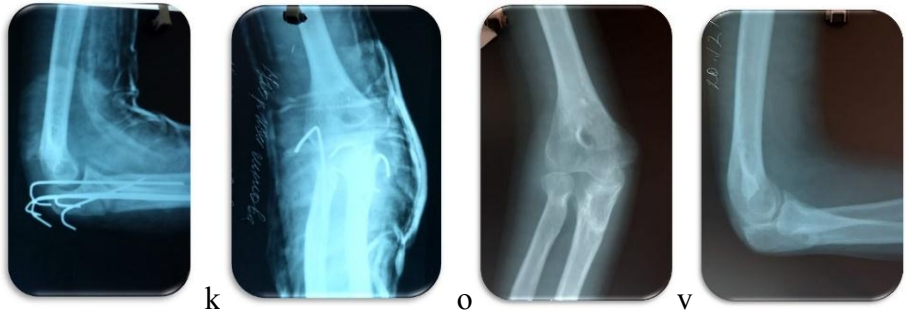Clinic examples:

Patient: A 13 years old. He came to our clinic 3 years after the injury with a diagnosis of complete dislocation of radial head. According to anamnesis he was treated with plaster cast. He was treated in a hospital for 10 days. Operation: A correction-extension osteotomy and osteosynthesis from the proximal part of the ulna and osteosynthesis of the radial head fixation with transarticular wires were performed using m.anconeus with plastic surgery of annular ligament. An additional longitudinal plaster cast was fixed(Fig №1a,b,s,d,e,j,z,l). Results of 9 months after surgery. The elbow flexion was 100% treated and extension movements were 97%. Rotational movements recovered to 80%. (fig.1(m, n,k,o,v,i)).



Clinic apperance and X-ray image of the patient at the time of application. The patient's elbow extension is 145⁰, and flexion 45⁰. The range of motion at the elbow joint is 100⁰.





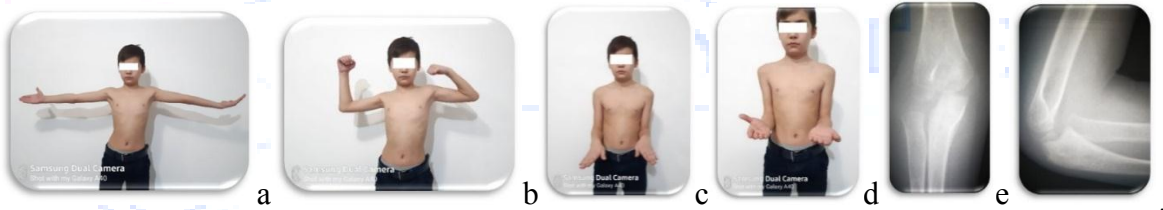
Clinical appearance and X-ray images of the patient 9 months after surgery. In the patient, the elbow joint extension is 170° and the flexion is 35°. Movement range is 135°

Pic. 1. Б-р. А. 13 years old., X-ray status and patient image.(a,b,s,d,e,j)Postoperative X-ray image(z,l). Achieved results and X-ray images (m,n,k,o,v,i).

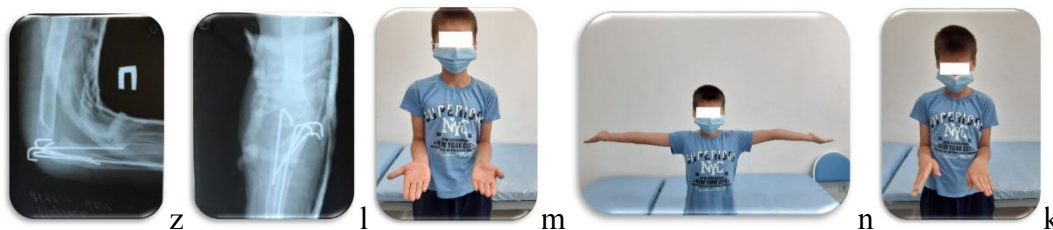
Patient: C 10 years old. Diagnosis: Bracht’s injury of the radial head dislocation. He came to our clinic after 4 months injury. According to anamnesis he was treated with a plaster cast in the hospital for 10 days.

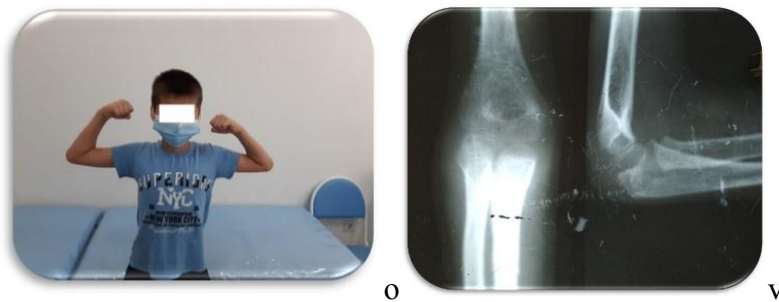
Operation: Osteosynthesis from the proximal portion of the elbow with a corrective osteotomy with wires and open reduction of radial head, plastic surgery of annular ligament by using m.anconeus, additional fixation with transarticular wires.

Fixated with an additional longitudinal plaster cast. Results after 7 months. The patient recovered with 95% flexion and 100% extension in the elbow joint. Rotational movements were recovered by 90% (pic 1),(pic 2)



Clinic appereance and X-ray image of the patient at the time of application. The extension is 180°, flexion is 90° as well. Movement range at the elbow joint is 90°.





Clinical appearance and X-ray images of the patient 7 months after surgery. The extension at the elbow joint is 180° , flexion is 40° as well. Movement range is 140° .

Pic. Patient. C. 10 years old. X-ray image and patient's picture.(a,b,s,d,e). X-ray images before and after surgery(z,l). Achieved results and X-ray image. (m,n,k,o,v)

To compare the close and long-term results of patients 23 of 55 patients who experienced ulnar osteotomy, and 22 who did not experience osteotomy on the elbow joint were included, and all patients were divided into 2 groups. That is, the first group included 22 patients which was not difficult for radial head reduction, and only these patients annular ligament plastic surgery was performed. In the second group, 23 patients experienced corrective and elongated osteotomy and plastic surgery of annular ligament. Broberg&Morrey indicator were used to evaluate the results. This assessment method is based on 4 indicators that focused on the good results of treatment of elbow injury and diseases, 1) elbow joint movement indicators, 2) rotational movements in the radius, 3) pain level at the elbow joint, 4) radial muscle strength. Patients were observed for a 1 year and the volume of movement in the clavicle was recovered from 2 to 6 months. The volume of rotational movements was recovered over a period of 5 to 7 months. Pain in the elbow joint disappeared within 3-6 months. The strength of the radial muscles was recovered over a period of 3 to 6 months. The reasons of achieving these results in a short time of period were individual rehabilitation of each patient and timely dynamic examination of patients as well as treatment rehabilitation. Early applying of patients after injury leads to the prevention of above-mentioned complications, completely recovering the elbow joint function and early rehabilitation of working ability.

Results were obtained from 23 and 22 patients who were observed for 6 months and 1 year respectively as well. Broberg&Morrey scale was used to get results. Both groups of patient were treated in the hospital for 10 days. Results were evaluated on a 100-point scale. 95-100 points is excellent, 84-94 points is good, 60-79 points is satisfactory, lower than 60 points is bad results respectively. Results are shown in table №1 below.

1 table

№	Group	Close results (over a period of 6 months)			
		Excellent	Good	Satisfactory	Bad
1	First	11 (50%)-	8 (36.4%)	2(9%)	1 (4.6%)
2	Second	5 (21.7%)	7 (30.4%)	9 (39.2%)	2 (8.7%)

2 table.

№	Group	Long-term results (after 1 year)			
		Excellent	Good	Satisfactory	Bad
1	First	11 (50%)	8 (36.4%)	2(9%)	1 (4.6%)
2	Second	13 (56.5%)	7 (30.4%)	2 (8.7%)	1 (4.4%)

Discussion

In order to evaluate results, the main factor of recovery of patients is the postoperative period. This is because it is more difficult to get good results for patients who have experienced osteotomy in 6 months' period, and also there is an issue of recovering ulnar bone after osteotomy, it takes 3 months in some patients as well. Then rehabilitation treatment may begin. Therefore, in the first table, the number of satisfactory treatment is high, the number of good results is closer to patients who experienced osteotomy, and the number of excellent results is noticeably lower. Continuing the research and seeing long-term results in the observed patients, it can be seen that, in most patients who experienced the elbow osteotomy, the results were mostly close to those who did not experience the ulnar osteotomy. Same situation also occurred with our patients. One patient from each of the two group was observed to have a contracture of the elbow joint. These patients were come for treatment after 3 years and it was found that they were treated with properly. The patient who experienced the ulnar osteotomy and had a contracture of the elbow joint, the degree of deformation of the proximal part of the elbow is higher than 45 degree, and the proximal part of the elbow is twisted around its own axis. Of course, during osteotomy, it is necessary to remove these deformations as much as possible and recover the congruence of the joint surfaces. But it is not always easy to completely eliminate such multi-surface deformations. Otherwise, in these patients, the joint surface in the ulnar bone may spread, causing joint instability. Therefore, in such cases, when the range of motion of the elbow joint is 100 degrees, it is advisable to assume that the recovery of the patient's ability to self-care is the main result.

In children, the diagnosis of chronic radial dislocations is not always satisfactory, so there are cases of chronical, valgus deformity and neurotrophic changes. The research shows that there are many methods in this direction, but it is clear that there are no common, all-satisfying methods among them. Therefore, it is necessary to eliminate the radial curvature and make the correct length of the radial bone by elbow osteotomy in radial head dislocations. The ulnar osteotomy should often be performed from the upper proximal part of the radius. It requires to perform an osteotomy at one localization and make two incisions to replace the radial head. Some doctors try to do two surgeries with one large incision. But we do not support this method, that is, we consider it is preferable to perform operation in two bones with one incision. In some patients, there is a risk that the operation process in two bones may cause inflammation of both bones and lead to contracture. Osteotomy should also be performed another method. This corrects the bone axis, ensuring the length of radial segment to 0,7-1,0 cm (in most cases the shortness occurs within this range mentioned above). After osteotomy of ulna, it is fixed by using wire (2-4 wires). In this case, osteotomy of the metaphyseal bone part results in faster healing and does not cause excessive discomfort. After the osteotomy, a place is made to radial head for reduction and the axis of the proximal part of the radius is

straightened. Hypotheses about using a plaster cast and transarticular wires for temporary fixation of radial head cause to contracture of the elbow joint was not observed by us.

Conclusion

In conclusion, the treatment of chronic dislocation of radial head in children is still important today. The main reason of occurring remains is late applying of patients. Our new method for the treatment of radial head dislocations shows its importance and optimality, and this method does not interfere with the corrective and elongating osteotomy performed on the ulnar bone. Using these two methods in the radial head dislocations gives us to recover function at the elbow joint and make an optimal radial length.

References:

1. Clare D.J., Corley F.J., Wirth M.A. Ipsilateral combination Monteggia and Galeazzi injuries in an adult patient: a case report // *J. Orthop. Trauma.* — 2002. — Vol. 16 (2), Feb. — P. 130-4
2. Дульцев И. А. Оперативное лечение застарелых вывихов и перелома-вывихов в локтевом суставе: Автореф. дис. ... канд. мед. наук. - С. Петербург, 2010. – 26 с.
3. Королёв С. Б., Павлов Д. Б. Диагностика и лечение перелома-вывихов типа Монтеджа: Пособие для врачей. - Н.Новгород, 1998. - С. 31.
4. Joseph L. L., Richard S. Y., Matthew A. F. et al. Divergent elbow dislocation with radial head shaft fracture, distal ulnar deformation and distal radioulnar joint instability: an unclassifiable Monteggia variant // *J Orthopaed Traumatol.* – 2014. – Vol. 15. – P. 63-67.
5. Андреев П.С., Скворцов А.П., Цой И.В. Хирургическое лечение застарелого перелома Монтеджа у детей и подростков // *Инновационные технологии в медицине.* 2014. Том 2. №4. С.19-22.
6. Овсянкин Н. А. Лечение последствий травм локтевого сустава у детей // *Актовая речь.* - С. Петербург, 2000. – С. 21.
7. Datta T., Chatterjee N., Pal A. K. et al. Evaluation of outcome of corrective ulnar osteotomy with bone grafting and annular ligament reconstruction in neglected Monteggia fracture dislocation in children // *J Clin Diagn Res.* – 2014. – Vol. 8, №6. – P. 101.
8. Jiangwei T., Mingzhang M., Guangiun L. et al. Biomechanical analysis of the annular ligament Monteggia fractures using finite element models // *Journal of Orthopaedic Surgery and Research.* – 2015. – Vol. 30, №10. – P. 1-6.
9. Овсянкин Н. А., Каземирский В. Е. Оперативное лечение детей с посттравматическими вывихами предплечья в локтевом суставе: Метод. реком. - Л., 1988. – 17 с.

10. Проценко Я. Н., Овсянкин Н. А., Поздеева Н. А. Методы лечения детей с травмами области локтевого сустава // Травматология и ортопедия России. – 2011. – Том 62, №4. – С. 147-151.
11. Cobanoglu M., Savk S. O., Cullu E. et al. Ipsilateral supracondylar humerus fracture and Monteggia lesion with a 5 year follow up: a rare injury in a young girl // BMJ Case Rep. – 2015. – Vol. 29.
12. Бабовников А. В. Новый способ хирургического лечения застарелых вывихов предплечья // Матер. сб. междунар. юбилей. научно-практич. конф. «Современные повреждения и их лечение». – Москва, 2010. – С. 44-45.
13. Сальников С. С., Гольцов Ю. А. Способ лечения застарелого перелома локтевой кости с вывихом головки лучевой кости // Описание изобретения к патенту РФ. 2007. – 4 с.
14. Kalamchi A. Monteggia Fracture-Dislocation in Children. Late treatment in two cases // J Bone Joint Surg. – 1986. - Vol.68-A. – P. 615-619.
15. Шевцов В.И., Швед С.И., Сысенко Ю.М. Чрескостный остеосинтез при оскольчатых переломах Курган: ДАММИ; 2002. С.244
16. Eamsobhana P., Kaewpornasawan K. Chronic Monteggia lesions treatment with open reduction and Z-lengthening with annular ligament reconstruction // J Med Assoc Thai. – 2012. – Vol. 95. – P. 47-53.
17. Emiko H., Nakamura R., Koh S. et al. Surgical treatment for chronic radial head dislocation // J Bone Joint Surg. – 2002. – Vol. 84. – P. 1183-1188.
18. Giovanni L. D., Alessandro M., Camilla B. et al. Outcomes after surgical treatment of missed Monteggia fractures in children // Musculoskeletal Surgery. – 2015. - Vol.99, №1. – P. 75-82.
19. Пат. 2012258 РФ, МКИ⁴ А 61 В 17/56 Способ лечения застарелого перелома локтевой кости с вывихом головки лучевой кости / С.С. Сальников, Ю.П. Гольцов (РФ). - № 4699339/14; Заявлено 31.05.89; Опубл. 15.05.94. Бюл. № 9.
20. Traitement de la fracture de monteggia negligee par allongement de l'ulna avec la technique d'Iizarov / Ph. Gicquel, B. De Billy, Cl. Karger et al. // Rev. Chir. Orthop. – 2000. – Vol. 86. -N 8. – P. 844-847.
21. Wattincourt, L. Fractures de Monteggia anciennes chez l'enfant. Traitement chirurgical: resultats a moyen terme / L. Wattincourt, R. Seringe // Chir. Orthop. – 2000. – Vol. 86, suppl. II. – P. 39.

22. Солдатов Ю.П., Макушин В.Д. Аппарат Илизарова: лечение патологии локтевого сустава с позиций доказательной медицины (монография). Саарбрюккен, Германия, 2016.-308С

